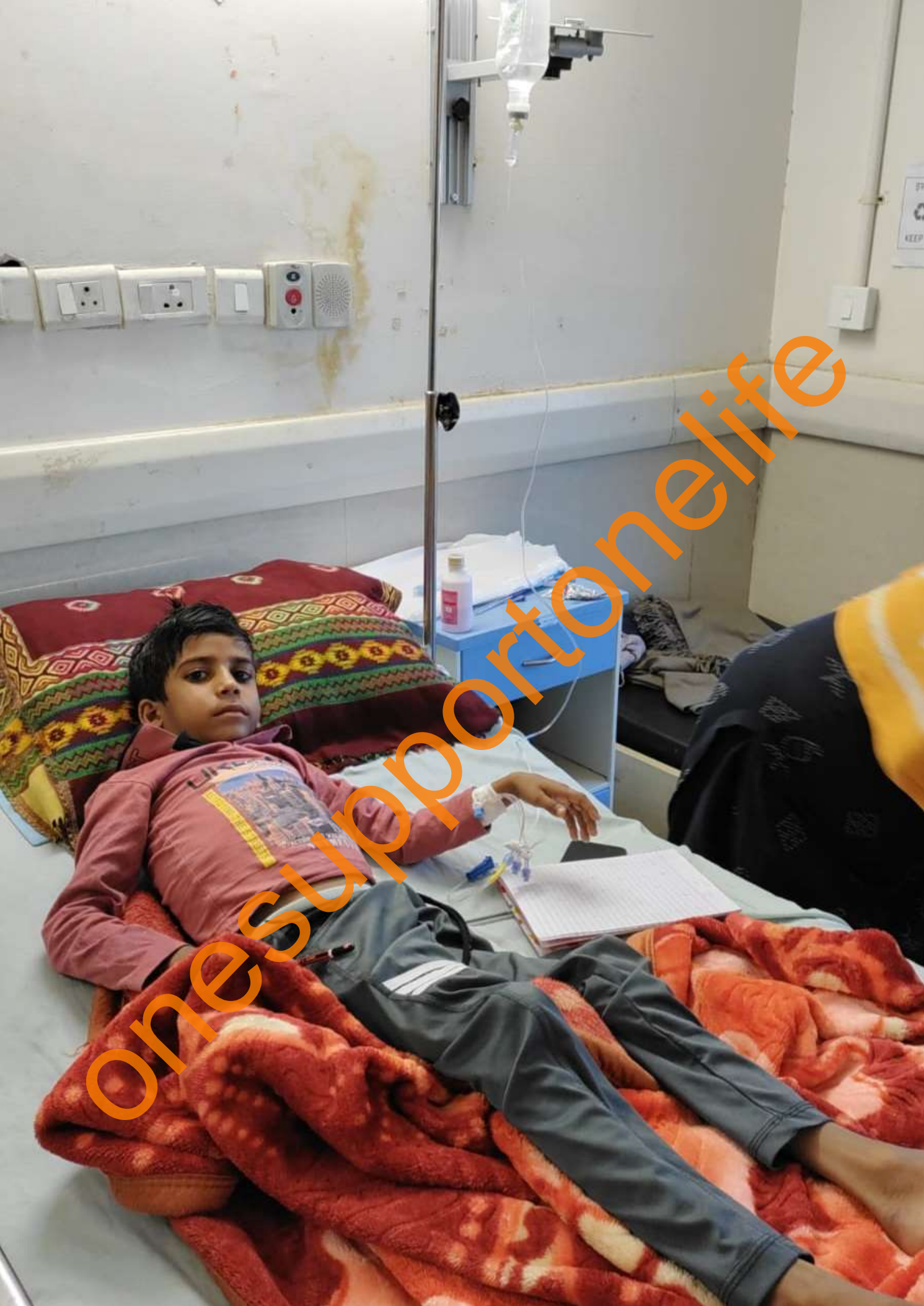
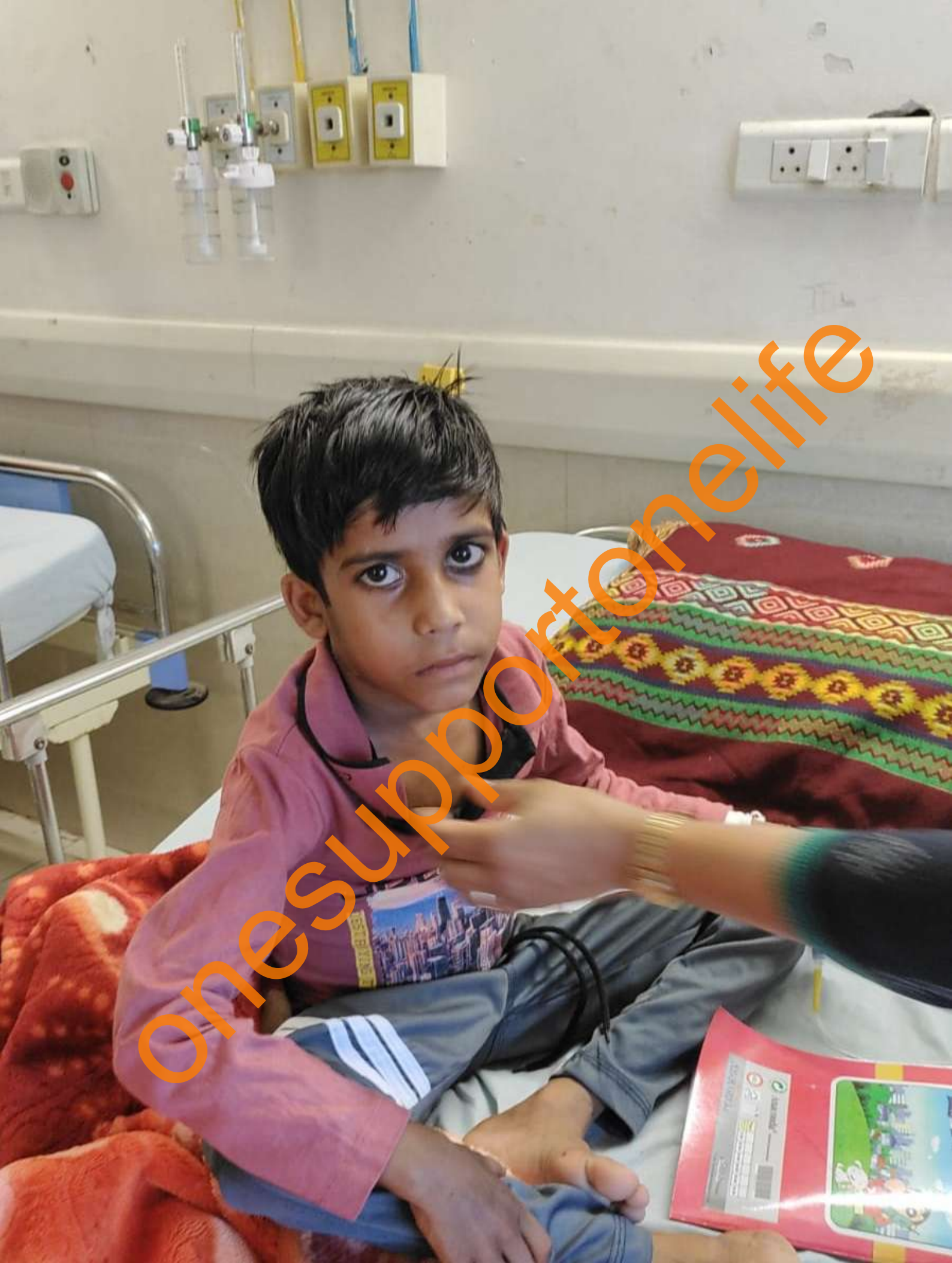


onesupportonlife



onesupportoneline



onesupportoneline



ONE SUPPORT ONE LIFE ORGANISATION

Registration No:- 148692

www.onesupportonelifelife.org

PATIENT NAME	APSAN
MOTHER NAME	RUKSAR
SEX / AGE	MALE / 7 YEAR'S
DISEASE NAME	CANCER, NON HODGKIN LYMPHOMA
HOSPITAL NAME	SUPER SPECIALITY PEDIATRIC HOSPITAL, NOIDA
ADDRESS	BAGICHI, SUNHERA, BHARATPUR, RAJASTHAN -321022
C.R NO	2022000844
BED.NO	03
DOCTOR NAME	DR. NITA RADHAKRISHNAN
TREATMENT REQUIRED	CHEMOTHERAPY
TREATMENT COST	4 LAKH INR
DEPARTMENT OF TREATMENT	PEDIATRIC ONCOLOGY



DEPARTMENT OF PEDIATRIC HEMATOLOGY ONCOLOGY
POST GRADUATE INSTITUTE OF CHILD HEALTH
NOIDA

NAME: Apsan
CR NO: 2022000844

AGE: 07years

SEX: Male

Ref no: SSPH/PHO/TE/2022/09

04/02/2022

To Whom It May Concern:

This is to certify that Apsan, 07 years Male, Son of Mr.Saddam and Mrs.Rukksar DOB: 28/07/2014, Resident of Bagichi, Sunhera, Bharatpur, Rajasthan-321022 has been diagnosed as suffering **Non Hodgkin Lymphoma**. He has been started on chemotherapy for the same. Kindly support for the next two chemo cycle an amount for 25 thousand.

The cost of treatment is estimated to be 4 Lakh INR

Chemotherapy (With BMT): 2 Lakh

Antibiotics: 1 Lakh

Blood Component and Miscellaneous: 1 Lakh

This is inclusive of the cost of investigations, Surgery, blood transfusions, antibiotics, antifungals and investigations. SSPHPGTI is an autonomous institute under Government of Uttar Pradesh. This estimate is being given for the purpose of applying for aid for treatment from state/central government.

Dr. Nita Radhakrishnan
5/2/22
Associate Professor & HOD

Department of Pediatric Hematology Oncology

PGICH, Noida

Dr. Nita Radhakrishnan
Associate Professor & Head
Paediatric Hematology Oncology
S.S.P.H & P.G.T.I., Sector-30, Noida

PROGRESS NOTES AND ORDERS

Apsara

Age

C.R.No.

Ward No.

Bed No.

Date & Time	Progress Notes	Orders
5/2/22	(1) Tab. prednisolone (10mg)	2-1-1 Tab (8am - 2pm - 10p)
0.71m	(2) 5ml Digene 5ml TDS	
5/2/22	Non-Hodgkin lymphoma C.R.D.	
	Biopsy report awaited	
1/0		
1008 / 7 hrs	child is maintaining satmahr in room air	
400 / urine	Respiratory distress.	
408 / w	no pain abdomen	
stool	Appetite intact	
not	accepting paringurine & stool	
pand	no bleeding	
	DIE	
	Gc-Sick Multiple w/ lymphoma	
	HR - 142/min	
	Temp - afebrile	
	RR - 34/min	
	SpO ₂ - 99% w/h R/I	
	CXR 2/2 showing lesions	
	w/h occasional w/ly	
	P/A soft non tender no I.	

Progress Notes

Date & Time

Adv

- (1) Tab Prednisolone
- (2) Syp Digene
- (2) Syp Ambroxol
- (4) IVF DNS 1000ml/24hr
- (5) Tab Allopurinol

5/2/22.
2:57pm.

Adv

- (1) IVF - DNS 2100ml/24hr
- (2) 1; Lantix 8mg w B.D
- (3) 1; Omex 6mg 10 8H
- (4) T-Pred.
Digene.
Ambroxol
Allopurinol

Pred. - 43mg daily

6/2/22
11:30pm.

NHL (report awaited)

examined ok.

1200ml	1750ml	stool once
1882ml		

Spon ~ 100g

uhls etc
no HSM

Adv

- (1) IVF / Lantix / Omex
- (2) T-Pred / Digene
T-Allo purinol
- (3) Syp Ambroxol

Progress Notes

Date & Time

8/2/22
11:00 AM

One of NHL C
steroid phosphate Day + 5
Rt facial palsy
no pt comp and
admission/andly will
no vomiting
no pain abdomen

J/O

2100 / 3200
1050 ml
3150 urine
ny
2hmv
51102

O/E

41-yr
HR 101/min BP 112/70
SpO2 99%
Temp afebrile
Cervical L4/L5 myeloma
No other tenderness

Adm

- 1) IV / Lanix / Emser
- 2) Tab Prednisolone 5mg
- 3) Tab Amilorone
- 4) Tab Acetaminophen
- 5) Emser J/O

Dundup

9/2/22
2 pm

NHL
Day + 5

ok -
vhs ok
no HSM

CBC - 9/1

Triple IT
to monitor



PROGRESS NOTES AND ORDERS

Ward No.
Age C.R.No. Bed No.

Date & Time	Progress Notes	Orders
7/2/22 2:50 pm	NHE. steroid prophax Day + 3	
	Improved no vomiting / diarrhea. Yo : 2/100 ml 1850 ml / stool 13/0 ml urine all	
	vhh ok SpO2 99% off O2. no HSM	
		<ul style="list-style-type: none"> • IVF / Vanix / Oment • T. Prednisolone • Gyp & Zine • Allopurinol
		<ul style="list-style-type: none"> • BM / ABX • CSF Gology
1 pm	<p>th</p> <ul style="list-style-type: none"> - No fresh complaints - vitals stable - CST] 9/11

onesupportonline

Date & Time	Progress Notes
BP 135/94 mmHg	Tab Anlong 5mg 1/2 tab QD
8/2/22 11:00 AM	Con of NHL Steroid prophylaxis Day 1
TPO 2100/1250 1200 ml 3300 mmHg ml	no complaints accepting orally with painful urine & stool no pain abdomen no respiratory distress
stool stima	DIE GC-free HR - 103/min RR - 26/min SpO2 - 99% R/A Temp afebrile Cervix soft as myometrium VIA soft non tender natter
AAN	<ol style="list-style-type: none"> 1) Tab Prednisolone / sub Diquin 2) Tab Allopurinol 3) Tab Amilor Anlong 4) IV Lasix / Emket 5) strict TPO

onesupphotofree

Patient ID	7 year	Patient Name	AFSHAN
Age	Male	Date	15-Jan-22
Gender		Ref Doctor	SMS

CECT CHEST AND ABDOMEN

FINDINGS:

Large homogeneously enhancing mass lesion is noted involving prevascular and visceral and paravertebral compartment of mediastinum (as per ITMIG classification) with encasement of aorta and its branches and bilateral internal mammary artery. Encasement and compression of SVC and its tributaries. Enlarged homogeneously enhancing lymph nodes noted in bilateral cervical level III, IV and V and bilateral axillary region.

Liver appears enlarged measuring 12.8 cm in size, normal in shape, outline and parenchymal attenuation. No focal lesion. Intrahepatic biliary radicles appear normal. Portal vein appears normal.

Spleen is mildly enlarged in size 8.8 cm, normal in size, outline and attenuation.

Bilateral kidneys show multiple well defined round hypoenhancing masses largest measuring 21 x 22 mm in upper pole (right kidney) and 18 x 21 in mid pole (left kidney).

Homogeneously enhancing upper retroperitoneal mass is noted encasing aorta, celiac trunk and contacting IVC measuring 23 x 38 mm in size.

Bilateral renal vessels appear normal.

Enhancing circumferential bowel wall thickening without luminal narrowing of jejunal loops.

CBD is unremarkable.

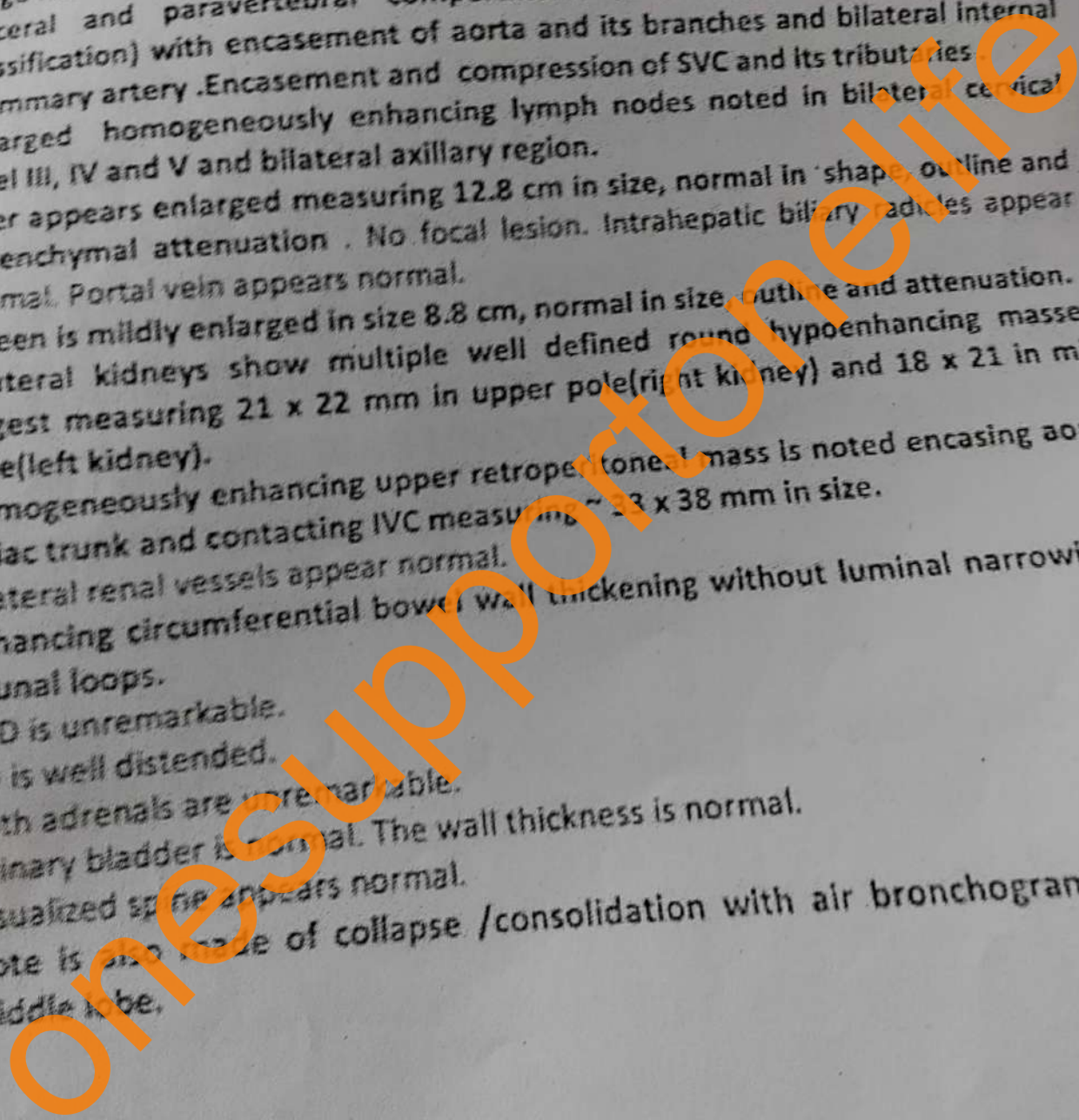
Gb is well distended.

Both adrenals are unremarkable.

Urinary bladder is normal. The wall thickness is normal.

Visualized spine appears normal.

Note is also made of collapse / consolidation with air bronchogram not middle lobe.



PATHOSCOPE

HISTO & CYTOPATHOLOGY CONSULTATION

BEHIND NWR,
NEAR JAWAHAR CIRCLE, JAIPUR-302017
☎ 7023911115, 7340211115

BRANCH: AKSHAT RETREAT, 412, 4TH FLOOR
OPP. SMS HOSPITAL GATE NO. 1,
TONK ROAD, JAIPUR-302001, ☎ 7340311115



Lab ID : 2201101858 -H22/01682
Name : AFSHAN
Sex/Age : MALE / 7 Years
Bill. Loc. :
Ref. By. :

Registration Date & Time : 27-Jan-2022 15:13
Sample Date & Time : 27-Jan-2022 15:13
Report Date & Time : 28-Jan-2022

HISTOPATHOLOGY

Specimen

Core biopsy, Cervical lymph node

Gross Description

Paraffin block submitted for IHC, reference no SMS 593/22

Microscopic Description

Shows lymphnodal tissue with fixation artefacts and effaced architecture by small sized atypical lymphoid cells.

Immunohistochemistry

CD-3:: Predominantly positive lymphoid cells
CD-20:: Few positive cells
CD-15:: Negative
CD-30:: Negative
CD-23:: Negative
CD-10:: Negative
TdT:: Negative/Noncontributory
Ki67 index:: 10-15%

Diagnosis

Lymphoproliferative disorder.

Owing to poorly preserved tissue/fixation artefacts; Immunomarkers performed are noncontributory to final diagnosis.

Advised:: Lymph node excision biopsy for proper comment/opinion.

----- End Of Report -----

All paraffin blocks labeled H22/01682 will be preserved for 2 years.



भारत सरकार
Government of India



Issue Date: 25/01/2021



अपसान
Apsan
जन्म तिथि / DOB: 28/07/2014
पुरुष / Male

9026 3761 8905

मेरा आधार, मेरी पहचान




भारतीय विशिष्ट पहचान प्राधिकरण
Unique Identification Authority of India



Print Date: 15/07/2021

पता: द्वारा: सद्दाम, बगीची, सुनहेरा, भरतपुर, राजस्थान,
321022

Address: C/O: Saddam, bagichi, Sunhera,
Bharatpur, Rajasthan, 321022



9026 3761 8905



1947




help@uidai.gov.in



www.uidai.gov.in



भारत सरकार
GOVERNMENT OF INDIA



सद्दाम

Saddam

जन्म तिथि/ DOB: 01/01/1992

पुरुष / MALE



2640 0274 7562

आधार - मेरा आधार, मेरी पहचान



भारतीय विशिष्ट पहचान प्राधिकरण
UNIQUE IDENTIFICATION AUTHORITY OF INDIA

पता:
आसिफ हसन, बगीची,
सुनहेरा, भरतपुर,
राजस्थान - 321022

Address:

S/O: Hassan, bageechi, Sunhera,
Bharatpur,
Rajasthan - 321022

2640 0274 7562

Aadhaar - Mera Aadhaar, Meri Pehachan